

Short Communication

COMPARATIVE DEGENERATIVE LIVER WITH AMALAR, CHLOROQUINE, COTECXIN AND FANSIDAR

E. O. JIMMY¹, I. F. USOH² AND E.J. AKPAN³

^{1*}DEPARTMENT OF PHYSIOLOGY, FACULTY OF BASIC MEDICAL SCIENCES, UNIVERSITY OF UYO,
AKWA IBOM STATE, NIGERIA.

^{2,3}DEPARTMENT OF BIOCHEMISTRY, FACULTY OF BASIC MEDICAL SCIENCES, UNIVERSITY OF
UYO, AKWA IBOM STATE, NIGERIA.

E-mail: medstedrecheo@yahoo.com



This work is licensed under a [Creative Commons Attribution 4.0 International License](https://creativecommons.org/licenses/by/4.0/).

ABSTRACT

A comparative histologic effects of chloroquine, fansidar, amalar and cotecxin on the liver was carried out on thirty (30) male and female albino rats for the period of twenty eight days (28) days. The liver with chloroquine administration showed congestion of the central veins and the pericentral hepacytes had mild degeneration as against the control group without the drug. However, in the fansidar drug group there was no dilation of the pericentral hepatocytes nor congestion and degenerative changes though the central veins were dilated. But the liver with cotecxin administration showed veinous dilation, congestion and infiltration of inflammatory cells into the central veins not seen in the control group. On the other hand, the liver's reaction to amalar drug only resulted in mild congestion of the central veins. It is shown in the study that cotecxin and chloroquine curative antimalarials continuous intake may cause liver cirrhosis. **Copyright © WJMMS, all rights reserved.**

Keywords: Liver, curative and preventive antimalarials, liver disease.

INTRODUCTION

The liver is a bilobed largest organ in the body situated in the upper part of the abdominal cavity. The cell constituents of the liver are arranged as hepatic lobules. The lobules are central in the organized functions of the liver being ushered with important vessels as portal vein, hepatic artery and a bile duct (Waugh and Grant, 200). Important functions of the liver include: metabolism of fat, carbohydrate, protein, iron, hormones and drugs. It is also characterized with vascular function e.g. storage and filtration of blood and the synthesis of blood coagulation factors. The excretory and secretory functions of liver are emphasized in drugs and hormones and the notable drugs are sulphonamides, penicillin and erythromycin, while the hormones include; thyroxine, oestrogen cortical and aldosterone, Oyebola, 2002.

The liver also form and secret bile, excrete bilirubin particularly the conjugation of it to arrest a disease situation; jaundice in excess circulation. It is also involved in protection function against foreign particle invasion e.g. bacteria through hepatic macrophages/activities. The liver is therefore very strategic in the overall body physiology and any harmful effect will affect aforementioned activities. The high stride in this investigation is the emphasis on physioanatomic friendly potent and sustainable preventive therapy against malaria to minimize drug effects as the disease is on the insurgence. This is to prioritize cost effective malaria management strategy while the most definite preventive measure; the vaccine is being awaited. Cotecxin, a dihydroartemisinin derivative antimalaria is used as an alternative drug for chloroquine resistance plasmodium falciparum strain due to its 98% efficacious rate than Lumenfantrine Artemeler. But both drugs are used as curative therapy for malaria disease. Fansidar and amalar are chemoprophylaxis i.e. for prevention against malaria.

These two drugs have same concentration pyrimethemine/sulphadoxine. Amalar is meant as substitute for fansidar resistant plasmodium falciparum strain. Importantly, cotecxin and amalar are new antimalaria drugs which pressure on usage is already very high and such is tending gradually towards self-medication, Jimmy et al, 2000. But these new drugs like any other new ones need to be epidemiological monitored routinely to avoid a more devastating physiologic effect than malaria.

MATERIALS AND METHODS

A total of thirty (30) albino rats weighing on average 0.08.14kg and fed with pellets and water daily were utilized for the study at the Faculty of Pharmacy animal house University of Uyo, Akwa Ibom State, Nigeria. The animals were assigned to six drugs groups with five animals per drug group including control.

DRUG ADMINISTRATION

The methods of Jimmy et al 2007, Bertram, 2004 and Robert et al, 1979 were used for the study. Four drugs, Amalar, Cotecxin, Chloroquine and Fansidar purchased from a licensed Pharmacy Shop in Uyo, Akwa Ibom State, Nigeria were used for the study. The drugs were administered orally by body weights of the animals using canula-by-passing the esophagus and delivered into the stomach, (Robert, 1979). But the standard preparation of the drugs was based on the average weight of man 70kg in curative dosages of chloroquine and cotecxin, and mg base and the preventive dosages of Amalar and Fansidar in mg base dosage. The control group was without any drug.

The effects of the drugs on the liver were observed for 28 days run and weekly split, a modified version of the previous study Jimmy et al 2007. This approach was to allow for cumulative effects likely without altering the 28 days model of WHO standard antimalaria and parasitologic monitoring (WHO 1982). However, the animals were not infected with malaria parasites, rather the effects of the drugs on the liver were observed for the same number of days.

HISTOLOGY

The animals were not injuriously handled but consent not obtained as there is no animal right in Akwa Ibom State or in Nigeria where the study was done. The animals were anesthetized with chloroform and the liver removed for necessary histology studies. The method of Druby and Wallington 1967 was used in the processing of the liver from all the animals and the results interpreted with photomicrographs.

RESULTS

The liver with chloroquine and cotecxin curative antimalarials showed different histologic features from those of preventive drugs; fansidar and amalar. Chloroquine affected the hepatocytes by congesting the central vein and degeneration of the hepatocytes, plate 1.

Also cotecxin affected the liver by dilation, congestion and infiltration of inflammatory cells, plate II. These were not observed in control, plate III. In the preventive drug groups, fansidar and amalar had mild effects on the liver, plate 4 and 5.

\




Plate 2 showing effect of cotecxin on liver



Plate 1 showing the effect of Chloroquine on liver



Plate 3 Showing the livers without drugs treatment

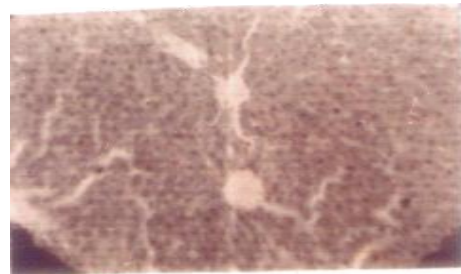


Plate 4 showing the effect of Fansidar on liver



Plate 5 showing effect of Amalar on liver

DISCUSSION

The study has shown specially that both the preventive and curative antimalaria drugs altered the normal histologic components of the liver with attendant physiologic consequences. While chloroquine markedly affected the central and pericentral portions, cotecxin caused dilation and infiltration of inflammatory cells into the central veins of the liver. Both actions of the two drugs led to degeneration of the liver cells showing smaller sizes than normal. This implies cellular damage as a result of hepatotoxicity, and such toxicity may lead to liver cirrhosis and myocardial infarction (Noslen, 1993).

The study is much concerned with the self medication attitude of health seekers, clinical and parasitological failure and the heavy revisiting or reinfection and the antimalaria regimen particularly, the curative.

The implications are many; the tendency of quicker hepatic pathology is high particularly with self medication these days especially chloroquine. It is documented that most people including untrained health providers e.g. the patent medicine dealers are not knowledgeable of the normal dosage of chloroquine, Jimmy et al 2000. In clinical and parasitological failure therefore, there is the tendency to repeat the first line treatment drugs or start the curative, preventive dosages. The resultant effects would be the cumulative concentration of these drugs overtime and per the half-life of the drugs too.

Though chloroquine is not very effective against the resistant strain of the malaria parasite, plasmodium falciparum but the effect on the liver as observed in our study is lesser than that of the cotecxin which should be a more potent drug against malaria. Here, the efficacy effect of cotecxin is reciprocated on the deleterious tones on the liver. The side effects of cotecxin than chloroquine may be due to the duration of intake which span up to seven days as against 3 days for the chloroquine and perhaps the drug concentration.

However, the seven days regimen period for this drug is a systematic parasite clearance approach which by this span, clinical and parasitological failure or success could be obtained. Alternative approach as that of chloroquine was not adopted for cotecxin in our study as the aim was the effects of the drugs following the standard prescription and treatment in the population for now. Perhaps, this is why the spelt mild effect on the liver but then the drugs concentration need be considered too. The effect of adulteration is not also ruled out as cotecxin is a new and expensive drug. Malaria causes enlargement of the body organs e.g. the spleen and the liver, it will be a double harmful effects if the treatment drugs also negatively affect such organs, meaning the collapse of the body physiology. There would therefore be additional increase in morbidity and mortality with curative drugs. The amalar and fansidar drugs showed mild effects on the liver in the study but then fansidar has the tendency of inducing diabetes (Jimmy 2007) and even amalar has its negative story.

Agreed that all drugs have one effect or the other on the body systems but such effects need be weighed as per the type of disease.

Malaria is the problem of all Africans affecting all persons in the continents daily. The daily infection results in daily treatment and also daily effects. The disease alone kills about 300,00 children annually in Nigeria and about lesser of this number in adult (Salako 1998). This means that those surviving the disease through daily treatment are working about with degenerative body systems.

The maiming tendencies of all the antimalaria drugs need be the concern of all the stakeholders in malaria management. This is why the pattern of approach by the roll back malaria organization need to be reviewed particularly on the pharmacologic inputs, intensity of surveillance, epidemiologic scope and research personnel.

The study recommends preventive therapy with less toxic antimalarials for at least a better physiologic resolution in malaria management.

REFERENCES

- [1] Bertram, G. (2004): In basic and clinical pharmacology, 9th edition, New York, Chicago, Sanfrancisco, London.
- [2] Druby, R. B. & Wallington (1967): In histological Techniques, 4th edition, Oxford University Press, New York.
- [3] Jimmy, E. O. Etim, Usoh F. I. (2007). Hypo and Hyperglycemia; Indicators for Comparative Physiologic Evaluation of Chloroquine, Fansidar Malareich and Maloxine, Acta Pharmaceutic Scientia, 49:65-70.
- [4] Jimmy, E. O., Achelona E., Orjis, (2000). Antimalarials dispending pattern by patent medicine dealers in rural settlements in Nigeria. Public Health (England), 114:282-285.
- [5] Nosten, F., Kuile T., Luxemburger, F. O., Woodow C; Kuyle D., Chong E., & Suphajcusiddhi T. (1993). Cardiac effects of antimalarial treatment with chloroquine: Lancet; Pumed, 341:1054-56.
- [6] Oyebola D. O. (2002): In Essential Physiology, Vol. 1 Nihort Press, Ibadan, Nigeria.
- [7] Robert, A. (1979). Gastric cytoprotection property of Prostaglandin. Gastroenterol. 77:762-769.
- [8] Waugh, A. and Grant, A. (2001): In Anatomy and Physiology in Health and illness, 9th edition baillere, Tindal, Chnchill living stone, Mosby, W.B. Saunders.
- [9] WHO (1982): In modern design of antimalaria drugs proceedings of a meeting held in Bethesda, Maryland USA.
- [10] Salako, L-A. (1998). Lecture on malaria mobilization any. Federal Ministry of Health, Nigeria.